COMPARATIVE STUDY OF SCLERAL FIXATION IOL AND GLUED IOL

[1]Dr. Jignesh Gosai, [2]Dr. Tanuj Limbasiya, [3]Dr.Urvi Patel & [4]Dr. Sunniva Dungdung
[1]Assistant Professor, M & J Institute of Ophthalmology, Ahmedabad, Gujarat.
[2]Consultant, Giridhar Eye Institute, Cochin, Kerala.
[3,4]Student, M & J Institute of Ophthalmology, Ahmedabad, Gujarat.

Received Oct. 03, 2017 Accepted Nov. 14, 2017

ABSTRACT ***PURPOSE****: To examine the IOL tilt, decentration, anterior chamber depth, refractive status and post-operative complications in patients undergoing scleral sutured IOL and glued IOL.* ***METHODS AND MATERIALS****: A prospective study of 66 eyes of 62 patients of aphakia surgical or optical was conducted. Pre and post operative visual acuity, intraocular pressure (IOP), fundoscopy, USG (Ultrasonography scan), UBM (ultrasound biomicroscopy with post operative complications were recorded.* ***RESULTS****: All patients underwent either scleral fixated IOL(SFIOL) or glued IOL with or without lensectomy and vitrectomy. 75% and 64.7% eyes achieved ≥20/60 BCVA in glued IOL and SFIOL respectively. Post operative IOL tilt and decentration was noted more in SFIOL.* ***CONCLUSIONS****: Glued IOL can be considered a superior modality of secondary IOL implantation with fewer complications and better visual correction.*

Key words: *scleral fixated IOL, glued IOL,*

INTRODUCTION

The endocapsular placement of an intraocular lens (IOL) is undoubtedly anatomically most preferable following successful cataract extraction. However, the presence of an unstable capsule-zonule complex or its absence, as with a dislocated lens or pseudoexfoliation syndrome, preempts the endocapsular fixation of the IOL. [14] The implantation of an IOL in the capsular bag provides stable fixation at a position closest to the nodal point of the eye. [9]

Aphakia (absence of crystalline lens from the patellar fossa) is corrected by spectacles, contact lens and intraocular lenses.

IOL implantation in eyes that lack posterior capsular support has been accomplished in the past by using iris-fixated IOL, anterior chamber (AC) IOL and transscleral IOL fixation through the ciliary sulcus or pars plana. [14]

Because of their anatomic location, scleral-fixated PC IOL's have a theoretic advantage over other IOL's with regard to complications, especially in eyes after trauma and in young patients. [23],[24],[2] They provide better visual acuity and binocularity, lower incidence of strabismus than contact lenses, and avoid the complications of AC IOL's, which are seen more with rigid closed loop IOLs than with open-loop and iris-claw IOL's. [2],[21],[22],[20],[17]

Glued intrascleral fixation is a technique that helps to implant a posterior chamber (PC) IOL in eyes with a deficient posterior capsule. A quick-acting surgical fibrin sealant derived from human blood plasma, which has both hemostatic and adhesive properties, [1] is used to seal the sclera flaps. Fibrin glue has been used in various medical specialities as a hemostatic agent to arrest bleeding and seal tissues and as an adjunct to wound healing. [11],[3]

METHODS AND MATERIAL

A prospective study of 66 eyes of 62 patients of aphakia (surgical or optical) of any age or gender were operated and followed up for 2 month. Patients were randomly allocated suture fixation or glue fixation.

The ethical standards outlined by the Medical Research Council were followed when contacting patients. A well-informed consent was taken. Preoperative and postoperatively visual acuity by Snellen's chart was assessed. Slit lamp Examination to assess and grade severity of inflammation, position of lens/IOL and to assess corneal edema was done pre and post operatively.

IOP measured by applanation tonometry – uncontrolled glaucoma was defined as an IOP of ≥ 25mmHg

Fundus examination – by indirect ophthalmoscopy to evaluate posterior segment for inflammation both pre and post operatively.

USG scan in cases of non visualization of fundus by indirect ophthalmoscopy and post operatively to examine for choroidal effusion, choroidal detachment, vitreous haemorrhage, retinal detachment.

UBM(ultrasound biomicroscopy)- performed postoperatively at 1 month and 3 months to examine anterior chamber depth, IOL centration and IOL tilt by vertical biometry .

Procedure

Standard 3 port vitrectomy is performed in cases of primary procedure of lensectomy with vitrectomy with SF/glued IOL in cases of secondary procedure of SF/glued IOL was done.

Routine scleral and routine glued fixation procedure were done. After secondary IOL implant 360 degree laser barrage was done thus reducing the chances of future retinal detachment.

RESULTS

Out of 66 patients 18 were female and 48 were males with mean age of around 49.5 years.

20 out of 66(30%) eyes had previous history of trauma which led to aphakia, 12 (18.18%) had subluxation and association with marfan's syndrome while 6 (9.09%) had diabetes and 4 (6.06%) had Hypertension.

Figure 1:Systemic association:- 12 (18.18%) out of 66 had subluxation and association with marfan's syndrome,6 (9.09%) had DM-2 and 4 (6.06%) had HTN.

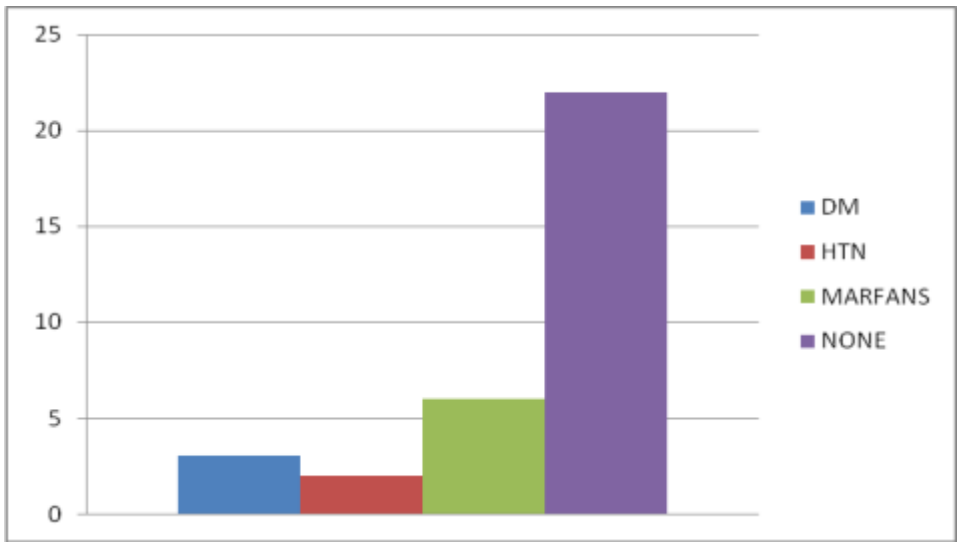

32 eyes underwent glued iol surgery and 34 underwent sclera fixated iol.

75% and 64.7% eyes achieved ≥20/60 BCVA in glued iol and sfiol respectively.

Post operative IOL tilt was noted in 25% and 70.6% eyes of glued iol and sfiol respectively.

Post operative IOL decentration was noted in 25% and 47.05% eyes of glued iol and sfiol respectively.

Table 1:Type of surgery and post operative iol tilt on ubm

	YES	NO	TOTAL
GLUED	8	24	32
SF	24	10	34
TOTAL	32	34	66

$X^2 = 6.858$; p= 0.0088 Yate's $X^2 = 5.155$ p = 0.023

P VALUE IS SIGNIFICANT AT 0.05 SIGNIFICANCE LEVEL (P<0.05) AND IOL TILT CAN BE TERMED SIGNIFICANTLY DIFFERENT IN BOTH THE TYPES OF SURGERY AT POST OPERATIVE WEEK 3.THIS SHOWS THAT IOL TILT IN GLUED IOL IS LESS AS COMPARED TO SFIOL .

Figure 2: chart showing post operative IOL tilt

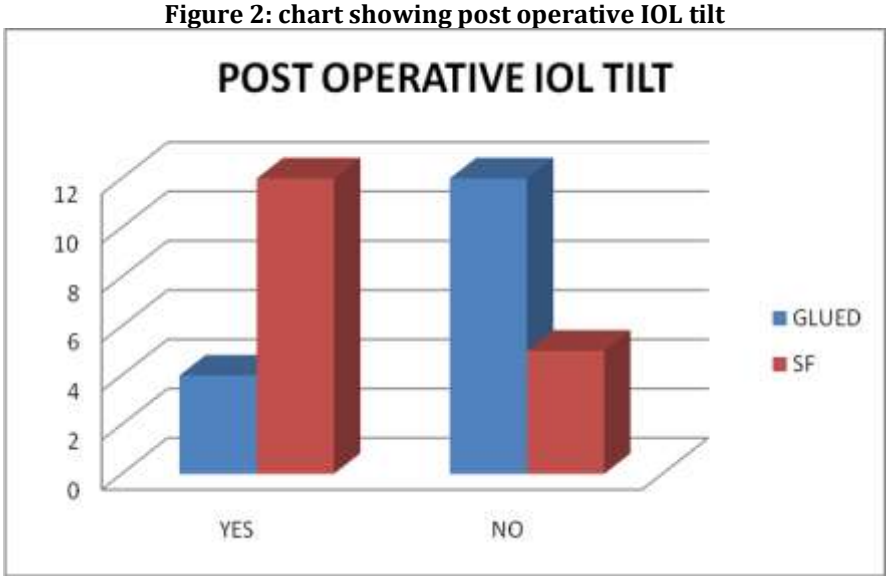

Table 2:TYPE OF SURGERY AND IOL CENTRATION

	CENTERED	DECENTERED	TOTAL
GLUED	24	8	32
SF	18	16	34
	42	24	66

Decentered in glued iol 25% and sfiol 47.05%

Post operative inflammation was significantly more ($p=0.03, p<0.05$) in sfiol than glued iol.

A higher number of complications like cystoid macular edema, hyphema, pigment dispersion, IOL tilt, IOL decentration were seen in sfiol (16/17) than glued iol(12/16).

Figure 3: chart showing complication in glued IOL and SFIOL

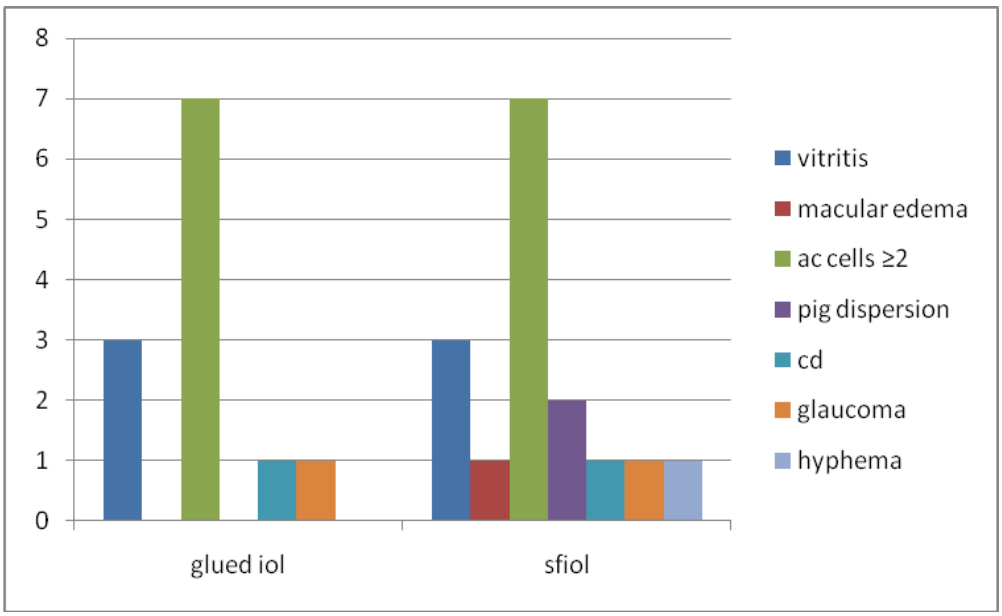

Most of the patients achieved a good BCVA, hence it can be concluded that secondary IOL implantation in the posterior chamber should be preferred as compared to other modalities of aphakia correction.

Table 3 :TYPE OF SURGERY AND POST OP. VISION AT 8 WEEKS

	≥20/40	≤20/60	TOTAL
GLUED	20	12	32
SF	22	12	34
	42	24	66

62.5% and 64.7% patients achieved ≥20/40 vision in glued iol and sfiol respectively.75% and 64.7% patients achieved ≥20/60 vision in glued iol and sfiol respectively.

Inspite of a greater rate of complications sfiol provided good visual rehabilitation, hence it could be used in patients not affording fibrin sealants.

DISCUSSION

Cataract surgery and intraocular lens (IOL) implantation has undergone dramatic evolution over last few decades.

Visual rehabilitation with an IOL is an ideal option in aphakic eyes with a secondary implant which may be a scleral-fixated posterior chamber IOL (SPCIOLs), an angle-supported anterior chamber IOL (AACIOLs), or an iris-fixated anterior chamber IOL (IACIOLs).(25)

With iris claw lenses, uveitis-glaucoma-hemorrhage syndrome has been reported. Iris-sutured intraocular lenses can cause cat-like pupil and iris chaffing and need sufficient iris stroma for fixation. [18]

In some cases, supplementary IOL implantation in the ciliary sulcus is a viable option.

Another alternative is transcleral fixation of an IOL which has gained popularity over the past 2 decades, most likely due to improvements in lens designs and implantation techniques. IOL fixation technique can be performed either by trans-scleral suturing or with the use of fibrin glue.

Sutured scleral fixated IOL's are associated with visually significant complications due to late subluxation, [8],[10] complications related to sutures [7][6] and secondary IOL implantation. In a histologic study, [8] IOL stability was the result of intact scleral sutures and not to fibrous encapsulation or correct placement of the haptic in the ciliary sulcus. IOL dislocation is likely to occur if sutures are inadvertently removed or if suture fatigue occurs. [23],[10] Two-point suture fixation carries a higher risk of axial IOL tilt, and 3 or 4 point fixation heightens the risk for complications .

Glue assisted intrascleral fixation differs from other sutureless techniques in a way that two partial scleral thickness flaps are made 180 degrees apart and scleral pockets are made at the edge of the flap base, parallel to the sclerotomy wound. The haptics are tucked in the scleral pockets and the flaps are then adhered to the base with the help of tissue fibrin glue. The glue also helps in sealing the sclerotomy site which would otherwise act as a filtration site and cause hypotony.
In such technique, postoperative tilt and decentration due to inadequate haptic position is of concern. In addition vitreo-retinal complications also occur. Therefore a comparative study for different techniques of scleral fixated IOLs was carried out.

Ganekal S(23) et al had a similar study of fifty patients (n=25 suture, n=25 glue). Post operative inflammation was significantly more (p=0.03,p<0.05) in sfiol than glued iol patients. Likewise, a higher number of complications were seen in sfiol (16/17) than glued iol(12/16) in our study.

Kumar DA(24) et al studied 208 eyes (185 patients) of glued intrascleral fixation foldable iol with mean follow-up of 16.7 months ± 10.2 (SD). The postoperative CDVA was 20/40 or better and 20/60 or better in 38.9% and 48.5% of eyes, respectively. Our study showed 62.5% and 75% eyes achieved 20/40 or better and 20/60 or better post operative BCVA in glued iol.

Agarwal(6) et al examined eyes with glued IOLs for inadequate capsule support with UBM. Optic tilt was measured in relation to the iris plane. There was no significant difference in ORA between eyes with tilt and eyes without tilt (*P*=.079). There was no significant correlation between ORA and IOL position. There was no correlation of optic tilt and postoperative vision or cylinder. In our study, out of 16 eyes,4 (25%) showed IOL tilt and 12(75%) showed no tilt. There was no association of BCVA and IOL tilt(p=0.26,p>0.05).

REFERNCES

1. Agarwal A, Kumar D A, Jacob S, Baid C, Agarwal A,Srinivasan S. Fibrin glue-assisted sutureless posterior chamber intraocular lens implantation in eyes with deficient posterior capsules. J Cataract Refract Surg 2008;34:1433-8.
2. Epley KD, Shainberg M, Lueder GT, Tychsen L. Pediatric secondary lens implantation in the absence of capsular support. J AAPOS 2001;5:301-6.
3. Fink D, Klein JJ, Kang H, Ergin MA. Application of biological glue in repair of intracardiac structural defects. Ann Thorac Surg 2004;77:506-11.
4. Ganekal S, Venkataratnam S, Dorairaj S, Jhanji V**. Comparative evaluation of suture assisted and fibrin glue assisted scleral fixated intraocular lens implantation**. J. Refract. Surg. 2012; 28:249–52.
5. HeilskovT, JoondephBC, OlsenKR, Blankenship GW. Lateendophthalmitis after transscleral fixation of a posterior chamber intraocular lens. Arch Ophthalmol 1989;107:1427
6. Kumar DA, Agarwal A, Packiyalakshmi S, Agarwal A, **In vivo analysis of glued intraocular lens position with ultrasound biomicroscopy**, J Cataract and Refractive Surgery,2013 July;39(7):1017-22
7. Kumar DA1, Agarwal A, Packiyalakshmi S, Jacob S, Agarwal A **Complications and visual outcomes after glued foldable intraocular lens implantation in eyes with inadequate capsules**.J Cataract Refract Surg. 2013 Aug;39(8):1211-8
8. Lubniewski AJ, Holland EJ, Van Meter WS, Gussler D, Parelman J, Smith ME. Histologic study of eyes with transsclerally sutured posterior chamber intraocular lenses. Am J Ophthalmol 1990;110:237-43.
9. Mc Allister AS, Hirst LW. Visual outcomes and complications of scleral-fixated posterior chamber intraocular lenses. J Cataract Refract Surg 2011;37:1263-9.
10. Mc Cluskey P, Harrisberg B. Long-term results using scleralfixated posterior chamber intraocular lenses. J Cataract Refract Surg 1994;20:34-9.
11. Mintz PD, Mayers L, Avery N, Flanagan HL, Burks SG, Spotnitz WD. Fibrin sealant: Clinical use and the development of the University of Virginia Tissue Adhesive Center.Ann Clin Lab Sci 2001;31:108-18.
12. Mowbray SL, Chang SH, Casella JF. Estimation of the useful lifetime of polypropylene fiber in the anterior chamber. J Am Intraocul Implant Soc 1983;9:143-7.
13. Parekh P, Green WR, Stark WJ, Akpek EK. Subluxation of suture-fixated posterior chamber intraocular lenses; a clinicopathologic study. Ophthalmology 2007;114:232-7
14. Por YM, Lavin MJ.Techniques of intraocular lens suspension in the absence of capsular/zonular support. Surv Ophthalmol 2005;50:429-62.
15. Price FW Jr, Wellemeyer M. Transscleral fixation of posterior chamber intraocular lenses. J Cataract Refract Surg 1995;21:567-73.
16. Price MO, Price FW, Werner L, Berlie C, Mamalis N. Late dislocation of scleral-sutured posterior chamber intraocular lenses. J Cataract Refract Surg 2005;31:1320-6.
17. Price, F.W. and Whitson, W.E. **Suprachoroidal hemorrhage after placement of a scleral-fixated lens.** *J Cataract Refract Surg*. 1990; 16: 514–515
18. Scharioth BG. IOL fixation techniques. Retinal Physician 2009;8:26-8
19. Scharioth G.B. Gabor, MD, Mitrofanis M. Pavlidis, MD Sutureless intrascleral posterior chamber intraocular lens fixation, Journal of Cataract & Refractive Surgery Volume 33, Issue 11, November 2007, Pages 1851–1854
20. Smiddy WE, Sawusch MR, O'Brian TP, Scott DR, Huang SS. Implantation of scleral-fixated posterior chamber intraocular lenses. J Cataract Refract Surg 1990;16:691-6.
21. Smith PW, Wong SK, Stark WJ, Gottsch JD, Terry AC, Bonham RD. Complications of semiflexible, closed-loop anterior chamber intraocular lenses. Arch Ophthalmol 1987;105:52-7
22. Stark WJ, Gottsch JD, Goodman DF, Goodman GL, Pratzer K. Posterior chamber intraocular lens implantation in the absence of capsular support. Arch Ophthalmol 1989;107:1078-83.
23. Vote BJ, Tranos P, Bunce C, Charteris DG, Da Cruz L. Long term outcome of combined pars planavitrectomy and scleral fixated sutured posterior chamber intraocular lens implantation. Am J Ophthalmol 2006;141:308-12.
24. Wagoner MD, Cox TA, Ariyasu RG, Jacobs DS, Karp CL. Intraocular lens implantation in the absence of capsular support. Ophthalmology 2003;110:840-59.
25. Y. M. Por and M. J. Lavin, "Techniques of intraocular lens suspension in the absence of capsular/zonular support," Survey of Ophthalmology, vol. 50, no. 5, pp. 429–462, 2005