A Survey on Glaucoma Detection Using Retinal Fundus Iamge

Karabi Barman* & Dr. Parismita Sarma**
*Department of Information Technology, Gauhati University under Guidance of Dr. Parismita Sarma.
**Assistant Professor, Gauhati University.

Received Jan. 15, 2018 Accepted Feb. 05, 2018

ABSTRACT *Glaucoma is a disease of eye causing optic nerve damage. The damage of the optic nerve occurs due to the increase in pressure within the eye and this presure is known as Intra Ocular pressure(IOP). It affects peripheral vision and eventually leads to blindness if left untreated. As this disease is non-curable, hence early detection is necessary in order to prevent the further progression of glaucoma. The Optic Disc (OD) and Optic Cup (OC) are the main parts in the fundus images which can be used in the diagnosis of the retinal diseases. The Cup to Disc ratio (CDR) is one of the important factor in Glaucoma detection. CDR is defined as the ratio between the Vertical Cup Diameter (VCD) to the Vertical Disc Diameter (VDD). Therefore, for the calculation of the CDR, OD and OC must be segmented properly. In OD segmentation process some problem arises due to the presence of Peripapillary Atrophy (PPA) around the boundary of the OD region. There are two types of PPA α and β.α occurs during the early stages of glaucoma. This PPA looks darker in comparison to OD and β occurs during the severe stages of glaucoma. β looks bright in comparison to OD. So, elimination of these PPA is necessary for the proper segmentation of the OD which gives the proper diagnosis of glaucoma.The described method is simple and robust which can be used for the detection of glaucoma.*

***Key words**: CDR, PPA, VCD, VDD, ISNT, FCM.*

1.INTRODUCTION:

Glaucoma is an irreversible eye disease which leads to complete blindness. It damages the optic nerve head called Optic Disc (OD). The intraocular fluid present in the eye exerts pressure on the eye known as the intraocular pressure (IOP). In normal condition, with the drainage system of the eye is working properly, the intraocular fluid can flow easily and prevent the buildingup of the pressure. However, in case of glaucoma, the drainage system becomes blocked and the intraocular fluid cannot drain easily. This causes a rise in the IOP, resulting in the damage of the optic nerve fibers. As this disease severity increases, the OD begins to form hollow structure and develops a cup shaped structure, which is called as Optic Cup (OC). The OC expand slowly with the progression of the disease and this causes peripheral vision block. Since glaucoma is asymptomatic in the early stages, therefore early detection of glaucoma is necessary in order to avoid the further progression of the disease. The ophthalmologists use the manual intervention for glaucoma detection, which is very much expensive and time consuming. So automatic glaucoma diagnosis is essential, which consume less amount of time compared to the manual detection helping the ophthalmologist to evaluate at a faster rate. Among various tools for imaging the fundus photography is the easiest and efficient way of early detection of glaucoma.

Human eye is a complex design which is the most efficient imaging device. The cornea is the transparent protective layer present at front of eye. The iris is the colored part of the eye which is responsible for the contraction and expansion of the eye so the it can let the pupil to get the right quantity of light to the eye. The direction of the light is controlled by the pupil to the lens. The lens aims at focusing the light on to the retina. Nerve fibers act as channel for the transmission images to the brain through the optic nerve. The intraocular fluid or aqueous humar, which is made by ciliary body is a clear fluid which is responsible for filling the front part of the eye. The fluid flows out through the pupil. Through the eye's drainage system, the fluid is then fused in to the bloodstream. This drainage system is a network of drainage canals surrounding the boundary of the iris. Eye pressure should be at normal level for that proper drainage is necessary. The intraocular fluid present in the eye exerts pressure on the eye known as the intraocular pressure (IOP). In normal condition, if the drainage. system of the eye is working properly then the intraocular fluid can flow easily and prevent a pressure build-up. However, in case of glaucoma, the drainage system becomes blocked and so the intraocular fluid cannot drain easily. This causes a rise in the IOP, resulting in the damage of the optic nerve fibers.

2. REVIEWED PAPER:

This section provides a previous study on various works related to our proposed work. In this section how, glaucoma can have detected by the different methods has been studied. The main features used for the detection glaucoma i.e. CDR, ISNT rule, NRR, PPA have been studied.

In this paper Kavitha et.al [1] proposed a method which used erosion and dilation as morphological operations for processing of optic cup and optic disc segmentation. It extracted the region of interest (ROI) and used labelling plot method on contour of the image. It was analysed that the component analysis method provided better cup to disc ratio (CDR).

In this paper Rüdiger Bock et.al [3] explained that Glaucoma as a neurodegeneration of the optic nerve is one of the most common causes of blindness. Because revitalization of the degenerated nerve fibers of the optic nerve is impossible early detection of the disease is essential. This can be supported by a robust and automated mass-screening. Hera a novel automated glaucoma detection system that operates on inexpensive to acquire and widely used digital color fundus images is used. After a glaucoma specific preprocessing, different generic feature types are compressed by an appearance-based dimension reduction technique. Subsequently, a probabilistic two-stage classification scheme combines these feature types to extract the novel Glaucoma Risk Index (GRI) that shows a reasonable glaucoma detection performance.

In this paper Joshi et.al [4] proposed a method which used region based active contour modelling in red color channel for optic disc segmentation. The results of this proposed method are compared with gradient vector flow (GVF) and chan-vese model (C-V model). It is analysed that the proposed method improved the boundary measure. It applied the concept of r-bends (vessel bends) information which use dynamic region of support (ROS) for corners detection followed by 2-D spline interpolation for non-uniform r-bends. The result after comparing with thresholding and ellipse fitting realize that proposed approach improved the result as compared with other approaches.

In this paper Noor et.al [6] proposed a method which for segmentation of optic cup and optic disc used the extracted region of interest. It analysed different color channels to identify the threshold value for optic disc by calculating the minimum, maximum and mean values. For detection of threshold values for optic disc it analysed red, green and blue channels. On the basis of threshold, retinal image was divided into first, second and background classes. Finally post processing was carried out using receiver operating characteristics (ROC). This method improved the parameters such as sensitivity, specificity and precision of cup to disc ratio (CDR).

In this paper K. Padmanaban et.al [7] proposed a method which used median filtering in green plane for pre-processing, for segmentation it used fuzzy c mean clustering on extracted region of interest and morphological operations for post processing.

In this paper Anusorn et al. [8] removed the blood vessels by using morphological operations and the median filter. The cup was segmented using the threshold in the green color channel and using a threshold level-set. The Canny algorithm for edge detection, K-means and a Variational Level-Set were used to segment the OD. After segmentation, an ellipse is drawn in each region to reshape the edges. The database used in the tests is private, containing 44 images. The method reached a Mae of 0.061 in the CDR calculation.

In this paper Cheng et al. [10] segmented the OD by eliminating the PPA region, which looks as bright as the OD. Optic disc segmentation from retinal fundus image is a fundamental but important step for automatic glaucoma diagnosis. The PPA is placed near the OD boundary. OD segmented is done by comparing three methods namely active contour model (ACM), fuzzy c-mean (FCM) clustering and artificial neural network (ANN). Here for OD segmentation the three methods are compared and as a result ACM gave the better result compared to the other two methods. Cheng et al. used fringe removal method to get the ROI.

The literature survey has been carried out thoroughly to make an in-depth analysis of the project related work done previously. From all the papers in the literature it is seen that CDR is one of the main indicator in case of glaucoma diagnosis. For CDR calculation OD and OC segmentation are mainly done. Several methods have been observed in the above papers for OD and OC. In literature it is also found that PPA also the important indicator for glaucoma diagnosis. Different types methods also used for the removal of PPA from the OD boundary for proper OD segmentation.

3.PROPOSED METHODOLGY:

This section covers the brief description of the CDR, PPA that are used for the diagnosis of glaucoma.Here we have mentioned about fuzzy c-means clustering method which is used to segment the OC and OD.

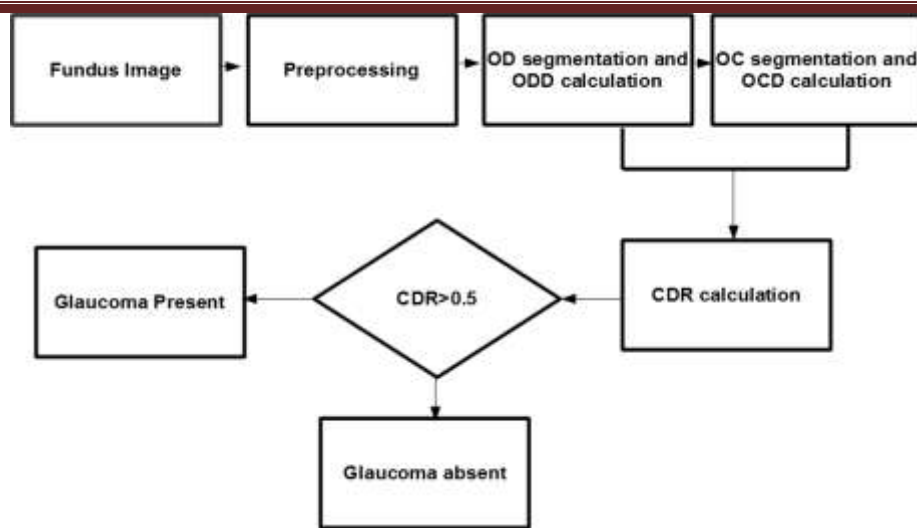

Figure 3.1: Block diagram of the proposed method

figure 3 .1 shows the various steps that are involved in our proposed system.
The input images taken from the various sources are cropped automatically by using software programmingto get the ROI. OD and OC need to segment by the proposed method. After OD and OC segmentation, CDR is calculated from the segmented OC and OD. The proper value of CDR gives the exact diagnosis of the glaucoma.

There are different types of features obtained from retinal images such as CDR, ISNT rule, PPA. etc. and these features can be utilized in case of glaucoma detection. A detailed study of the literature isdiscussed which reveals that the CDR is the most commonly and widely used feature for the diagnosis of glaucoma. From the literature, it is also found that PPA also takes important part in case of glaucoma detection.

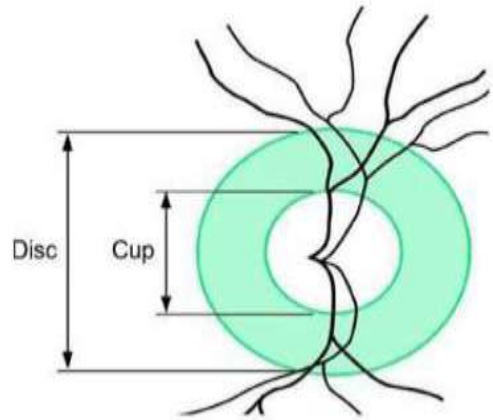

Fig:3.2 Evaluation of CDR from OD and OC [2]

According to study when IOP increases then the cup area will increase slowly and this happens because of the existence of glaucoma. The CDR value is used for examining the increase in cup area. There are different ways to measure the CDR for instance, the CDR can be defined in terms of area, vertical length and horizontal length of both OD and OC. Clinically, the CDR is the ratio of the vertical cup diameter (VCD) to vertical disc diameter (VDD).

$$CDR = \frac{vertical\,cup\,diameter(VCD)}{vertical\,disk\,diameter(VDD)}$$

The CDR with the value less than 0.5 gives the normal images, whereas CDR value greater than 0.5 gives the glaucomatous images [15].

PPA

PPA is the region which is sometimes confused as a part of the disc. There are two reasons for this

a) It is looked almost similar to OD.
b) Because of its curved shape it forms another ellipse along with the OD.

When there is a PPA in the retinal image, it indicates that the patient is suffering from glaucoma . In case of severe glaucoma PPA covers the whole OD region, while in case of early glaucoma it covers only some portion of the OD area. PPA can be divided in to two types namely:
(i**) α PPA**: It occurs during the early stages of glaucoma. This PPA looks darker in comparison to OD
(ii) **β PPA**: It occurs during the severe stages of glaucoma. It looks bright in comparison to OD.
Figure 3.3 shows the α and β PPA.

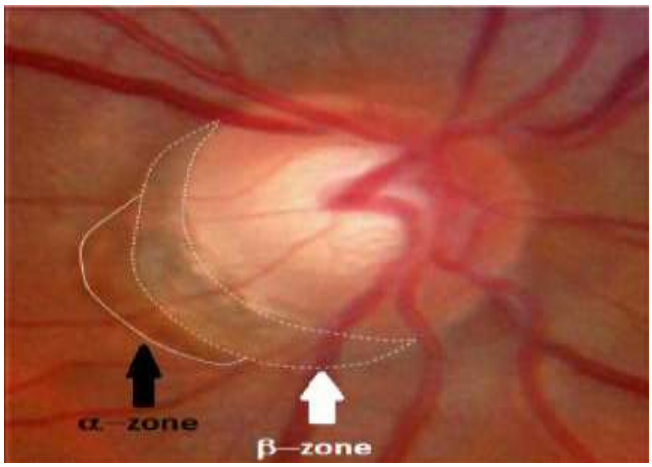

Figure 3.3: Retinal fundus image showing α and β PPA

It is difficult to segment the OD from PPA region because both looks similar, but in this proposed method using fuzzy c means algorithm it can be segmented out easily.

Pre-processing

Pre-processing stage includes cropping the image to get region of interest (ROI). Fuzzy c means is a simple and robust method which is proposed in this workfor segmentation of OD. Thepre-processing step is very much essential to boost up any segmentation process. As the requirement is to calculate the ODD and OCD, hence it will be more beneficial to automatically crop a ROI containing OD. Normally, processing with the whole image consumes more time, so ROI is extracted from the retinal sub image which will consume less amount of time. After that morphological operations erosion and dilation were used to get more proper image.

Morphological operation

Morphology is based on image analysis. It is mainly based on mathematical theoryof sets; these sets are known as the object of the image. Here, the set is defined by the grayscale images. A structuring element is taken with the main image and Intraction between the image and structing element is used for dilation and erosion. These operations were used to erase the blood vessel within the optic disc and smooth the intensity profiles around the centre of optic disc.

Erosion

Erosion is a basic morphological operation. Erosion in case of gray scale image is the replacement of a gray value a point by the minimum intensity value with the flat structuring element. So, erosion in pointwise with the image A and the flat structuring element E can be defined as

$$A\_E\ (x) = \min \{A(z): z_{\rho}Sx\}$$

where x indicates location of a pixel in the image.

Dilation

Dilation is a basic morphological operation. Dilation in case of gray scale image is the replacement of a gray value a point by the maximum intensity value with the flat structuring element. So, dilation in pointwise with the image A and the flat structuring element E can be defined as

$$A \oplus E\ (x) = \max \{A(z): z_{\rho}Sx\}$$

where x indicates location of a pixel in the image

Fuzzy c-means

The fuzzy c-means (FCM) algorithm is a clustering algorithm developed by Dunn, and laters on improved by Bezdek. It is useful when the required number of clusters are pre-determined; thus, the algorithm tries to put each of the data points to one of the clusters. What makes FCM different is that it does

not decide the absolute membership of a data point to a given cluster; instead, it calculates the likelihood (the degree of membership) that a data point will belong to that cluster. Hence, depending on the accuracy of the clustering that is required in practice, appropriate tolerance measures can be put in place. Since the absolute membership is not calculated, FCM can be extremely fast because the number of iterations required to achieve a specific clustering exercise corresponds to the required accuracy. Fuzzy c-means (FCM) is a clustering method which aims at allowing one object to be a part of two or more clusters. In case of pattern recognition this technique is commonly used. It is mainly aims optimizing the objective function as given by the equation.

$$F_n = \sum_{i=1}^{M} \sum_{j=1}^{D} u_{ij}^{n} \|y_i - d_j\|^2, 1 \leq n < \infty$$

where n is the real number greater than one, u_{ij} is the degree of membership of $y_j$in the clusterj.
y_i is the d-dimensional measured data, dj is the d-dimensional cluster centre, norm term gives the resemblance between a measured data and centre.
Fuzzy clustering method is an iterative process which tries to minimize the objective function as given in equation above equation and the membership function u_{ij} and cluster centres dj is updated by following equation.

$$u_{ij} = \frac{1}{\sum_{k=1}^{d} \frac{\|y_i - d_j\|}{\|y_i - d_k\|}^{\frac{2}{n-1}}}, d_j = \frac{\sum_{k=1}^{d} u_{ij}^{n} \cdot x_i}{\sum_{k=1}^{d} u_{ij}^{n}}$$

The iteration will be stop when

$$max_{ij} \mid u_{ij}^{(k+1)} - u_{ij}^{k} \mid < \xi$$

where ξ is the termination criterion which lies between 0 and 1
In case of standard FCM, the optimization is done when pixels near to their centroid gives high membership value and those pixels which are far away gives low membership values. In case of standard FCM the major problem is the absence of spatial information. Since noise and some non-homogeneous boundaries causes problems in the FCM, it is important to use spatial information on the standard FCM. The use of the spatial information makes the method more robust and noise free. For this reason in future we will try to incorporate spatial fuzzy c means clustering algorithmA new fuzzy level set method has been developed which exploit the results of spatial fuzzy clustering to initialize the level set function.

OD and OC segmentation

The second step is the OD and OC segmentation. This includes working principle of the method used for the segmentation of the OD and OC. This includes theoretical considerations of the proposed method.
The OD is important for glaucoma detection. Human eye receives a light and transmit through the optic nerve to the brain. The OD is also the leaving point of the optic nerve of the eye. The OD is also the origin of the blood vessels network. Optic nerve carries numerous numbers of neurons from the eye towards the brain in normal human eye. The OD is considered as the one of the main factor for the detection of glaucoma. The OD looks brighter compare to the surrounding in the fundus images.The segmentation of OD and OC are explained below.

SEGMENTATION OF OPTIC DISC(OD)

Segmentation of OD is annecessary in order to identify their features such as fovea, macula, optic cup etc. By recognizing the changes in shape, size and colour that is produces in OD glaucoma can be identified. Thus, OD segmentation and its analysis isused in the diagnosis of glaucoma. So proper OD segmentation is very much important in the diagnosis of glaucoma. In addition, OD segmentation plays vital role in the Diabetic Retinopathy (DR)

SEGMENTATION OF OPTIC CUP(OC)

OC is the white, cup-like area in the centre of the OD. The OD is divided in to two region namely central bright region called the cup and peripheral region that is neuroretinal rim. Enlargement of the cup region is the one of the main indicator for the detection of glaucoma. Due to the presence of numerous numbers of

blood vessels in OC region compare to OD, the segmentation of OC becomes difficult. The boundary between the OC and OD is non-distinguishable due to which it is difficult to segment the OC from the OD region. In the proposed method we have to use Cup to Disc Ratio(CDR) as one of the main factor for glaucoma detection. The OD and OC have to segment using proposed method. After that we need to calculate the ratio of the vertical cup diameter to the vertical disk diameter.

Larger value of CDR gives more risk of glaucoma. In the boundary of the OD region there exist some atrophy region which almost similar to the OD region. So, exclusion of this region that is PPA (per papillary atrophy) from the OD boundary gives the proper boundary of the OD.

4. RESULT:

In this section, at first input images are taken. After that it is converted to gray scale image. Thenbinary thresholding and morphological operations dilation and erosion were used to enhance the image. Fig 4.1 shows the original fundus image. This image was converted to gray scale as shown by fig 4.2. Then binary threshold is applied to subtract the background which is shown by fig 4.3. In fig 4.4 the region of interest (ROI image) is shown.

Fig 4.1: Original image (fundus image of the human eye)

Fig 4.2: Gray scale image

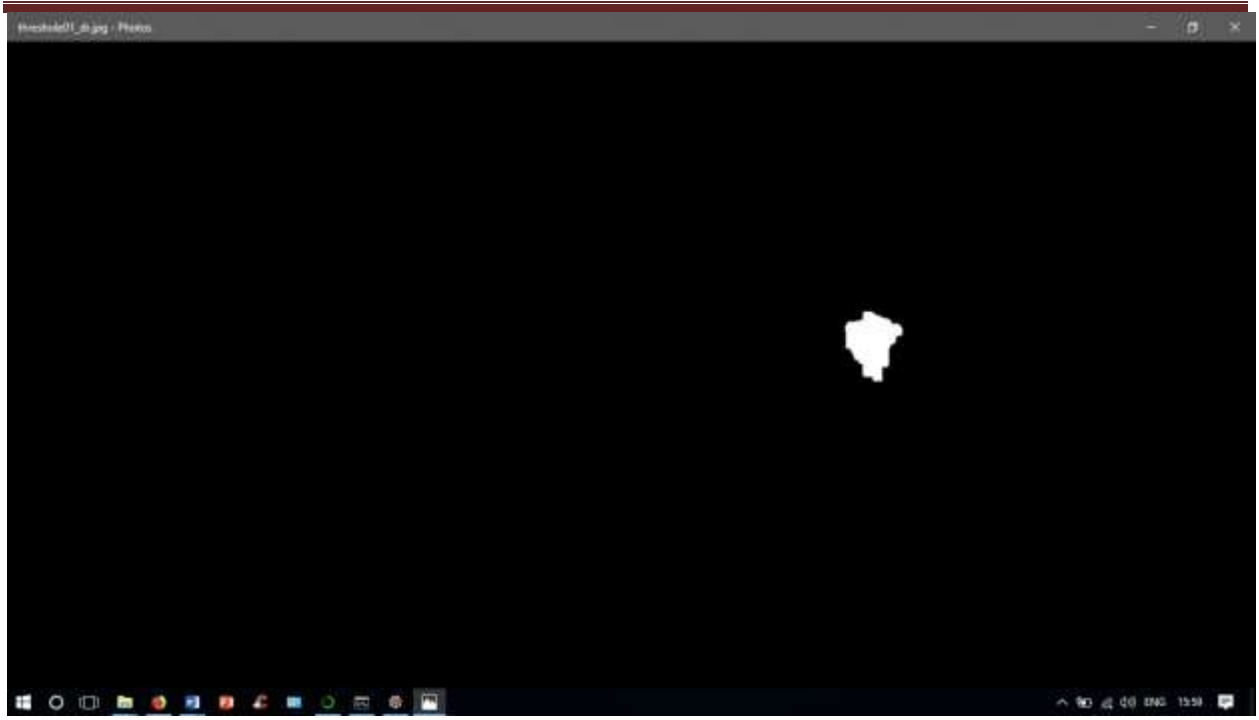

Fig 4. 3: Experimental result for background substraction (threshold image)

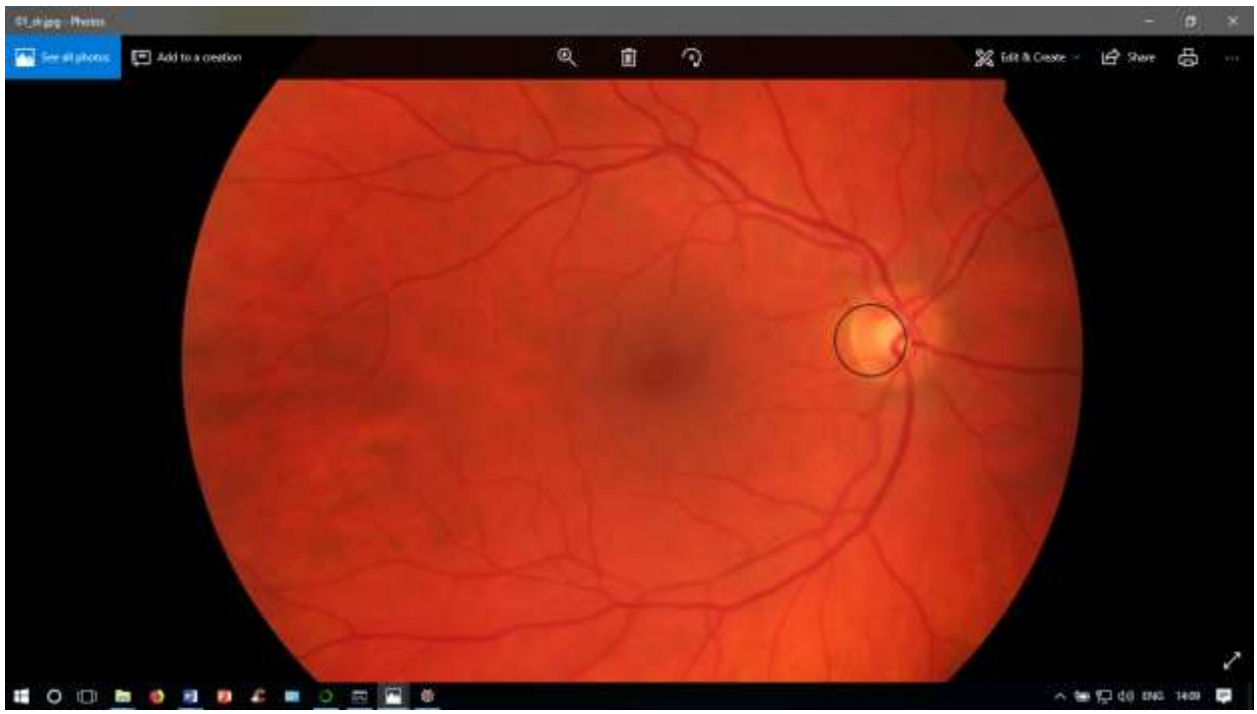

Fig4.4: Experimental result for region of interest detection (ROI image)

5. CONCLUSION AND FUTURE WORK:

Glaucoma is an eye disorder which causes complete vision loss in the severe stages. Progression of the disease can be avoided if it is detected in the early stages. However, glaucoma has been detected by the manual intervention which is time consuming. Therefore, the development of the automatic detection techniques can help the ophthalmologists in the detection of the disease in time and inexpensive manner. In this work, an approach for glaucoma detection has been proposed. The proposed method uses the CDR as the one of the main factor for glaucoma detection. The OD and OC have to segment using proposed method.

After that It need to calculate the ratio of the vertical cup diameter to the vertical disk diameter. The CDR is well known parameter in case glaucoma diagnosis. Larger value of CDR gives more risk of glaucoma. For CDR calculation, OD and OC should be properly segmented. In the boundary of the OD region there exist some atrophy region which almost similar to the OD region. So, exclusion of this region that is PPA (perpapillary atrophy) from the OD boundary gives the proper boundary of the OD. The CDR with the value less than 0.5 gives the normal images, whereas CDR value greater than 0.5 gives the glaucomatous images.

In the next semester we will try to implement the fuzzy c means clustering method for segmenting the OC and OD. The proposed method uses the CDR as the one of the main factor for glaucoma detection. The OD and OC have to segment using proposed method. After that it need to calculate the ratio of the vertical cup diameter to the vertical disk diameter. Larger value of CDR gives more risk of glaucoma. In the boundary of the OD region there exist some atrophy region which almost similar to the OD region. So, exclusion of this region that is PPA (perpapillary atrophy) from the OD boundary gives the proper boundary of the OD. The CDR with the value less than 0.5 gives the normal images, whereas CDR value greater than 0.5 gives the glaucomatous images.

REFERENCES:

1. S. Kavitha, S. Karthikeyan, and K. Duraiswamy, "Early detection of glaucoma in retinal images using cup to disc ratio," in *Computing Communication and Networking Technologies (ICCCNT), 2010 International Conference on*. IEEE, 2010, pp. 1–5.
2. J. Cheng, J. Liu, Y. Xu, F. Yin, D. W. K. Wong, N.-M. Tan, D. Tao, C.-Y. Cheng, T. Aung, and T. Y. Wong, "Superpixel classification based optic disc and optic cup segmentation for glaucoma screening," *IEEE Transactions on Medical Imaging*, vol. 32, no. 6, pp. 1019–1032, 2013.
3. R. Bock, J. Meier, L. G. Ny´ul, J. Hornegger, and G. Michelson, "Glaucoma risk index: automated glaucoma detection from color fundus images," *Medical image analysis*, vol. 14, no. 3, pp. 471–481, 2010.
4. G. D. Joshi, J. Sivaswamy, K. Karan, and S. Krishnadas, "Optic disk and cup boundary detection using regional information," in *Biomedical Imaging: From Nano to Macro, 2010 IEEE International Symposium on*. IEEE, 2010, pp. 948–951
5. Noor Elaiza, Abdul Khalida, Noorhayati Mohamed Noor, Norharyati Md. Ariff, "Fuzzy C-Means (FCM) for Optic Cup and Disc Segmentation with Morphological Operation", Elsevier, Procedia Computer Science, International Conference on Robot PRIDE 2013-2014 - Medical and Rehabilitation Robotics and Instrumentation, ConfPRIDE 2013-2014, vol.42, pg:255-262, December2014.
6. N. Noor, N. Khalid, and N. Ariff, "Optic cup and disc color channel multi-thresholding segmentation," in *Control System, Computing and Engineering (ICCSCE), 2013 IEEE International Conference on*. IEEE, 2013, pp. 530–534
7. K. Padmanaban and Dr.K. Jagadeesh kannan, "Localization of Optic Disc Using Fuzzy C Means Clustering", International Conference on Current Trends in Engineering and Technology, (ICCTET), pg: 571-573, 2013.
8. B. Anusorn, W. Kongprawechnon, T. Kondo, S. Sintuwong, and K. Tungpimolrut, "Image processing techniques for glaucoma detection using the cup-to-disc ratio," Thammasat International Journal of Science and Technology, vol. 18, no. 1, pp. 22–34, 2013.
9. Hafsah Ahmad, Abubakar Yamin, Aqsa Shakeel, Syed Omer Gillani, Umer Ansari, "Detection of glaucoma using Retinal Fundus images," 2014 International Conference on Robotics and Emerging Allied Technologies in Engineering (iCREATE) Islamabad, 978-1-4799-5132-1/14/$31.00 ©2014 IEEE.
10. J. Cheng, J. Liu, D. W. K. Wong, F. Yin, C. Cheung, M. Baskaran, T. Aung, and T. Y. Wong, "Automatic optic disc segmentation with peripapillary atrophy elimination," in Page *Engineering inMedicine and Biology Society, EMBC, 2011 Annual International Conference of the IEEE*. IEEE, 2011, pp. 6224–6227.
11. M. Lotankar, K. Noronha, and J. Koti, "Detection of optic disc and cup from color retinal images for automated diagnosis of glaucoma," in *Electrical Computer and Electronics (UPCON), 2015 IEEE UP Section Conference on*. IEEE, 2015, pp. 1–6.
12. Khan, S. A. Khan, U. U. Yasin, I. ul Haq, and U. Qamar, "Detection of glaucoma using
13. retinal fundus images," in *Biomedical Engineering International Conference (BMEiCON), 2013 6th*. IEEE, 2013, pp. 1–5.
14. M. Bertalmio, G. Sapiro, V. Caselles, and C. Ballester, "Image inpainting," in *Proceedings of the 27th annual conference on Computer graphics and interactive techniques*. ACM Press/Addison- Wesley Publishing Co., 2000, pp. 417–424.
15. J. Majumdar, "A threshold based algorithm to detect peripapillary atrophy for glaucoma diagnosis," *International Journal of Computer Applications*, vol. 126, no. 12, 2015.
16. Evaluation *of the Cup-to-Disk ratio (CDR).*, Std., 2014. [Online]. Available: http://s160131.gridserver.com.
17. DERIONS-DB Database, Std., Oct 2014. [Online]. Available: http://www.ia.uned.es/*ejcarmona/DRIONS-DB.html